



## Trigeminal Neuralgia (facial pain)

### Overview

Trigeminal neuralgia is extreme pain and muscle spasms in the face. Attacks of intense, electric shock-like pain can occur without warning or be triggered by touching specific areas of the face. Although the exact cause of trigeminal neuralgia is not fully understood, a blood vessel is often found compressing the nerve. Medication, injections, surgery, and radiation may be used to treat the pain. Each treatment offers benefits, but each has limitations. You and your doctor should determine which treatment is best for you.

### What is trigeminal neuralgia?

Neuralgia is severe pain caused by injury or damage to a nerve. The trigeminal nerve is the fifth (V) cranial nerve, which arises from the brainstem inside the skull. It divides into three branches and then exits the skull to supply feeling and movement to the face (Fig. 1):

- Ophthalmic division (V1) provides sensation to the forehead and eye.
- Maxillary division (V2) provides sensation to the cheek, upper lip, and roof of the mouth.
- Mandibular division (V3) provides sensation to the jaw and lower lip; it also provides movement of the muscles involved in biting, chewing, and swallowing.

When the trigeminal nerve becomes irritated, an attack of intense pain results. Also called tic douloureux because the pain can cause uncontrollable facial twitching, trigeminal neuralgia interferes with many aspects of a person's life. Typical trigeminal neuralgia involves brief instances of intense pain, like an electrical shock in one side of the face. This pain comes in repeated waves that last an hour or more. The patient may initially experience short, mild attacks, with periods of remission. But trigeminal neuralgia can progress, causing longer, frequent attacks of searing pain.

### What are the symptoms?

Patients describe an attack as a "pins and needles" sensation that turns into a burning or jabbing pain, or as an electrical shock that may last a few seconds or minutes. Everyday activities can trigger an episode. Some patients are sensitive in certain areas of the face, called trigger zones, which when touched cause an attack (Fig. 2). These zones are

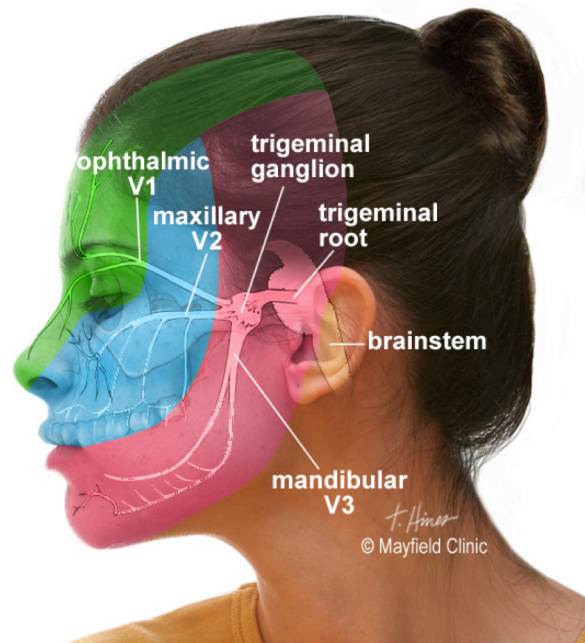


Figure 1. The trigeminal nerve supplies feeling and movement to the face. It has three divisions that branch from the trigeminal ganglion: ophthalmic division (V1) provides sensation to the forehead and eye, maxillary division (V2) provides sensation to the cheek, and mandibular division (V3) provides sensation to the jaw.

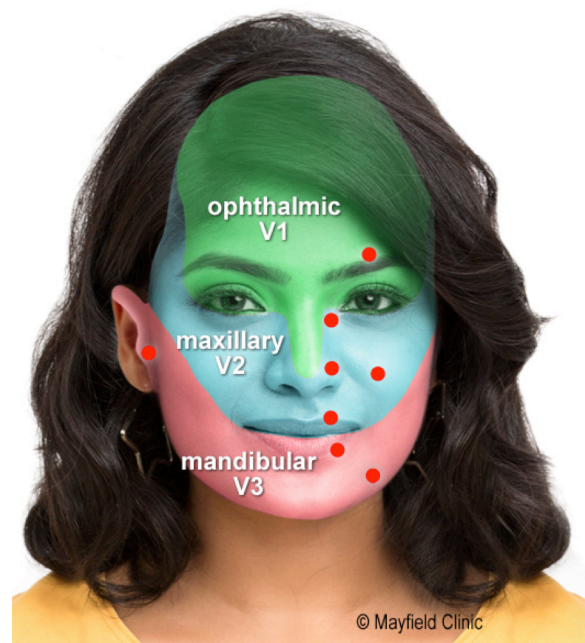


Figure 2. Facial areas of trigger zones. Trigger points (circles) have the greatest sensitivity.

usually near the nose, lips, eyes, ear, or inside the mouth. Therefore, some patients avoid talking, eating, kissing, or drinking. Other activities, such as shaving or brushing teeth, can also trigger pain.

The pain of typical trigeminal neuralgia usually has the following features:

- 1) Affects one side of the face
- 2) Can last several days or weeks, followed by a remission for months or years
- 3) Frequency of painful attacks increases over time and may become disabling

A less common form of the disorder, called atypical trigeminal neuralgia, causes a less intense, constant, dull burning or aching pain. This pain sometimes occurs with occasional electric shock-like stabs that may last a day or more. Atypical facial pain is more difficult to treat.

### What are the causes?

Many believe that the protective sheath of the trigeminal nerve deteriorates, sending abnormal messages along the nerve. Like static in a telephone line, these abnormalities disrupt the normal signal of the nerve and cause pain. Several factors can cause the deterioration of this protective sheath, including aging, multiple sclerosis, and tumors; but most doctors agree that it is most often caused by an abnormal vein or artery that compresses the nerve.

Some types of facial pain can result from an infected tooth, sinus infections, shingles or post-herpetic neuralgia, or previous nerve injury.

### Who is affected?

Trigeminal neuralgia affects 5 in every 100,000 people and occurs slightly more in women than men. Patients are usually middle age and older. Some people with multiple sclerosis also develop trigeminal neuralgia.

### How is a diagnosis made?

When a person first experiences facial pain, a primary care doctor or dentist is often consulted. If the pain requires further evaluation, a consultation with a neurologist or a neurosurgeon may be recommended. The doctor examines and touches areas of your face to determine exactly where the pain is occurring and which branches of the trigeminal nerve may be affected.

The underlying causes of trigeminal neuralgia are rarely serious. However, the possibility of a tumor or multiple sclerosis must be ruled out. Therefore, a magnetic resonance imaging (MRI) scan is usually performed. An MRI FIESTA scan can detect any blood vessels compressing the nerve (Fig. 3). The diagnosis of trigeminal neuralgia is made after carefully assessing the patient's symptoms.

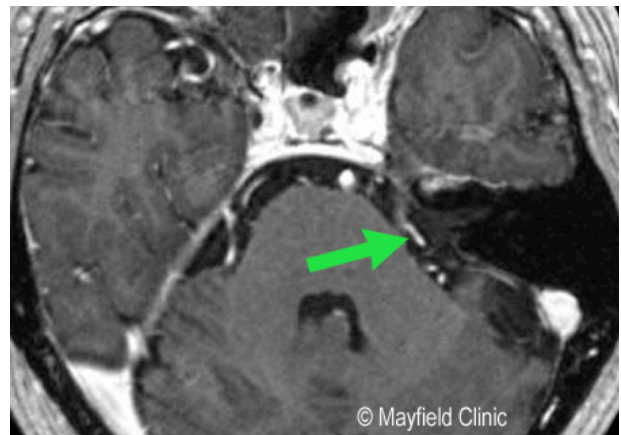


Figure 3. FIESTA MRI can detect blood vessels (arrow) that may be compressing the trigeminal nerve.

### What treatments are available?

A variety of treatments are available, including medication, surgery, needle procedures, and radiation. First-line treatment is usually medication. When medications fail to control pain or cause intolerable side effects, a neurosurgeon may be consulted to discuss other procedures.

#### Medication

Over-the-counter drugs such as aspirin and ibuprofen are not effective against trigeminal neuralgia. Anticonvulsants and muscle relaxants are prescribed to block the pain signals from the nerve. These medications are the initial treatment for trigeminal neuralgia and are used as long as the pain is controlled and the side effects do not interfere with a patient's activities. About 80% of patients experience at least short-term pain relief with medications. For effective pain control, medications must be taken on a regular schedule to maintain a constant level in the blood.

- **Anticonvulsants**, such as carbamazepine (Tegretol), oxcarbazepine (Trileptal), gabapentin (Neurontin), phenytoin (Dilantin), lamotrigine (Lamictal), and pregabalin (Lyrica) are used to control trigeminal neuralgia pain. If the medication begins to lose effectiveness, the doctor may increase the dose or switch to a different medication. Side effects may include drowsiness, unsteadiness, nausea, skin rash, and blood disorders. Therefore, patients are monitored routinely and undergo blood tests to ensure that the drug levels remain safe and that blood disorders do not develop. Multiple drug therapy may be necessary to control pain (e.g., Tegretol combined with Neurontin).
- Muscle relaxants, such as baclofen (Lioresal), are sometimes effective in treating trigeminal neuralgia. Side effects may include confusion, nausea, and drowsiness.

## Surgery

The goal of surgery is to stop the blood vessel from compressing the trigeminal nerve, or to cut the nerve to keep it from sending pain signals to the brain. Surgical procedures, which are performed under general anesthesia, involve opening a hole in the skull (called a craniotomy) and require a 1- to 2-day hospital stay.

- **Microvascular decompression (MVD)** is a surgery to gently reroute the blood vessel from compressing the trigeminal nerve by padding the vessel with a sponge. A 1-inch opening is made in the skull behind the ear, called a craniotomy. This opening exposes the trigeminal nerve at its connection with the brainstem. A blood vessel is often found compressing the nerve. After the nerve is freed from compression, it is protected with a small Teflon sponge (Fig. 4). The sponge remains in the brain permanently.

MVD provides immediate pain relief in 95% of patients [1]. About 20% of patients have pain recurrence within 10 years. The major benefit of MVD is that it causes little or no facial numbness. The major disadvantages are the risks of anesthesia and of undergoing an operation near the brain.

- **Sensory rhizotomy** is the irreversible cutting of the trigeminal nerve root at its connection to the brainstem. A small opening is made in the back of the skull. A stimulation probe is used to identify the motor root of the nerve. The motor root, which controls the chewing muscles, must be preserved. The sensory root fibers, which transmit the pain signals to the brain, are severed (Fig. 5). Cutting the nerve causes permanent facial numbness and should only be considered for recurrent pain that has not responded to other treatments.

**Peripheral neurectomy** is a type of surgery that can be performed to the nerve branches by exposing them on the face through a small skin incision. Cutting the supraorbital nerve (branch of V1 division) may be appropriate if pain is isolated to the area above the forehead. Cutting the infraorbital nerve (branch of V2 division) may be performed if pain is limited to the area below the eye along the upper cheekbone. Cutting the nerve causes complete facial numbness in the region the nerve supplies.

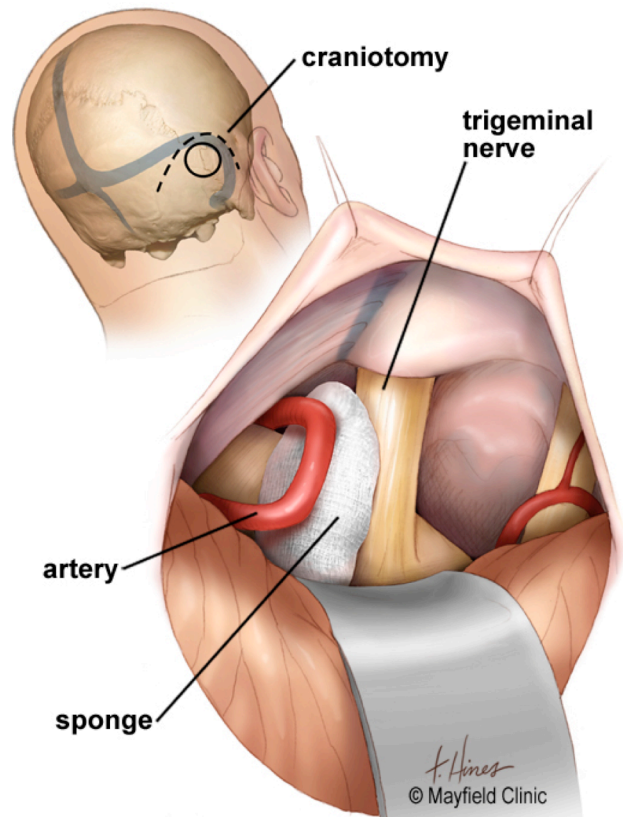


Figure 4. During MVD, a sponge is inserted between the trigeminal nerve and the blood vessel to relieve the compression that causes the painful neuralgia attacks.

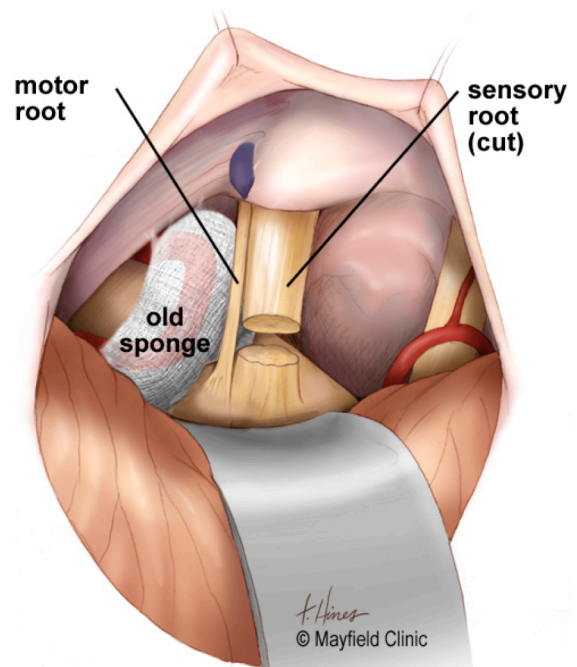


Figure 5. During sensory rhizotomy, the sensory root fibers are cut, but the motor root is preserved.

### Stereotactic Radiosurgery

Radiosurgery is a noninvasive outpatient procedure that uses highly focused radiation beams to destroy some of the trigeminal nerve root fibers that produce pain. The two main technologies are the Leksell Gamma Knife and linear accelerator systems such as the BrainLab Novalis. A stereotactic head frame or facemask is attached to the patient's head to precisely localize the nerve on an MRI scan and to hold the head perfectly still during treatment. Highly focused beams of radiation are delivered to the trigeminal nerve root (Fig. 6). In the weeks after treatment, a lesion (injury) develops where the radiation occurred.

Pain relief may not occur immediately but rather gradually over time. As a result, patients continue to take pain medication for a period of time. The success of radiosurgery becomes clear when pain medication is reduced or eliminated. After 4 weeks, about 50% of patients will experience pain relief without medication or with reduced medication. After 8 weeks, 75% will have pain relief without medication or with reduced medication [3]. Complications include facial numbness and dry eye. In about 30% of patients, pain recurs 3 to 5 years after treatment [4]. Repeat radiosurgery can be effective; however, the risk of facial numbness is increased.

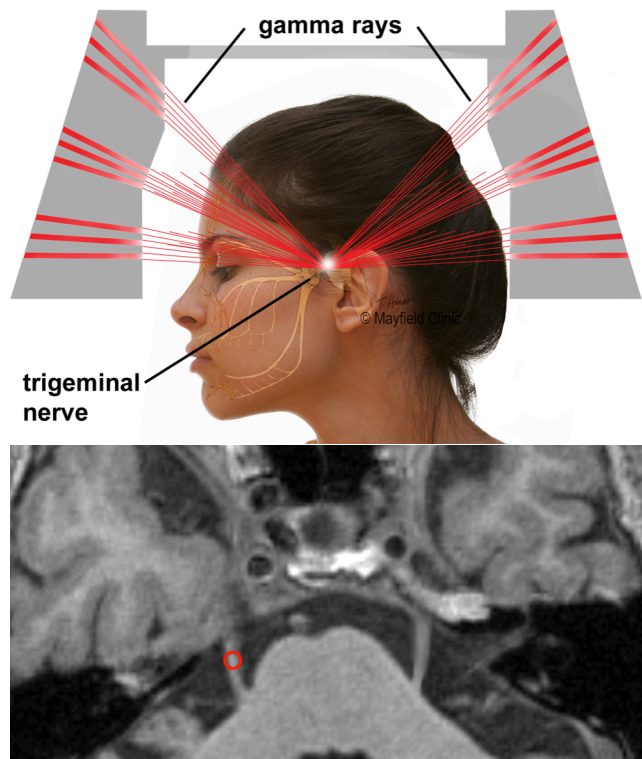


Figure 6. During radiosurgery, the patient's head is immobilized and beams of radiation are focused on the trigeminal nerve (top). The MRI (bottom) shows a red circle radiation dose delivered on the cisternal segment of the trigeminal nerve to damage the fibers.

### Outpatient needle procedures

Needle procedures are minimally invasive techniques for reaching the trigeminal nerve through the face without a skin incision or skull opening. They are performed with a hollow needle inserted through the skin (percutaneous) of the cheek into the trigeminal nerve at the base of the skull (Fig. 7). The goal of rhizotomy or injection procedures is to damage an area of the trigeminal nerve to keep it from sending pain signals to the brain. Damaging the nerve causes mild to major facial numbness in that area. A degree of facial numbness is an expected outcome of the procedure and is necessary to achieve long-term pain relief. These outpatient procedures are typically performed under local anesthesia and light sedation. Patients usually go home the same day.

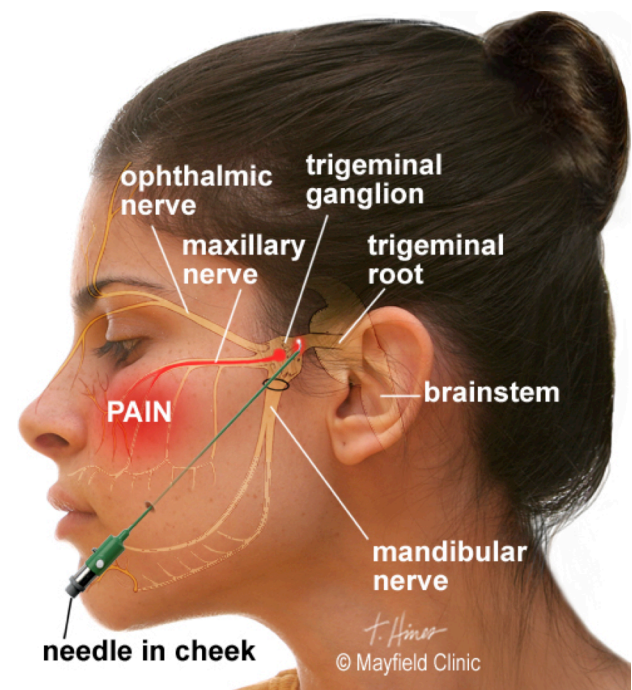


Figure 7. For needle procedure, a hollow cannula is inserted near the corner of the mouth. It is passed through the cheek and into a hole in the skull to reach the trigeminal ganglion. Through the cannula an electrode, liquid glycerol or balloons are passed.

- **Radiofrequency rhizotomy**, also called Percutaneous Stereotactic Radiofrequency Rhizotomy (PSR), uses a heating current to selectively destroy some of the trigeminal nerve fibers that produce pain. While the patient is asleep, a hollow needle and electrode are inserted through the cheek and into the nerve. The patient is awakened, and a low current is passed through the electrode to stimulate the nerve. Based on the patient's feedback, the surgeon positions the electrode so that tingling occurs where the painful attacks are located. Once the pain-causing area is located, the patient is put back to sleep and a heating current is passed through the electrode to damage only that portion of the nerve (Fig. 8A).

PSR provides immediate pain relief for 98% of patients [1]. About 20% of patients experience pain recurrence within 15 years. Medication, repeat PSR, or another surgical procedure can be considered. Complications may include double vision, jaw weakness, loss of corneal reflex, dysesthesia (troublesome numbness) and, very rarely, anesthesia dolorosa. Partial facial numbness in the area where the pain existed is expected. Other complications, such as blurred vision or chewing problems, are usually temporary.

- **Glycerol injection** is similar to PSR in that a hollow needle is passed through the cheek to the nerve. The needle is positioned in the trigeminal cistern (a fluid-filled area in the ganglion) (Fig. 8B). Glycerol is injected into the cistern to damage some of the trigeminal nerve fibers that produce pain. Because the location of the glycerol cannot be controlled precisely, the results are somewhat unpredictable.

Glycerol injection provides immediate pain relief in 70% of patients [2]. About 50% of patients experience pain recurrence within 3 to 4 years. As with PSR, partial facial numbness is expected, and complications are similar.

- **Balloon compression** is similar to PSR in that a hollow needle is passed through the cheek to the nerve. However, it is performed under general anesthesia. The surgeon places a balloon in the trigeminal nerve through a catheter. The balloon is inflated where fibers produce pain (Fig. 8C). The balloon compresses the nerve, injuring the pain-causing fibers. After several minutes the balloon and catheter are removed.

Balloon compression provides immediate pain relief for 80% of patients [2]. About 20% of patients experience pain recurrence within 3 years. Complications may include minor numbness, chewing problems, or double vision.

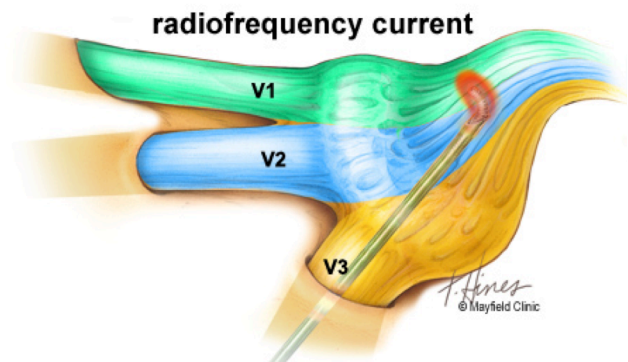
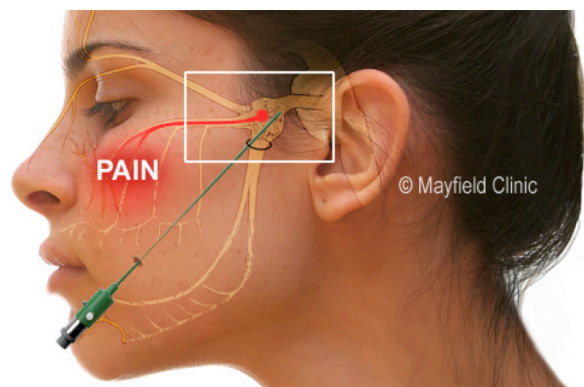


Figure 8A. In radiofrequency rhizotomy, a heating current selectively destroys nerve fibers in V1, V2, or V3.

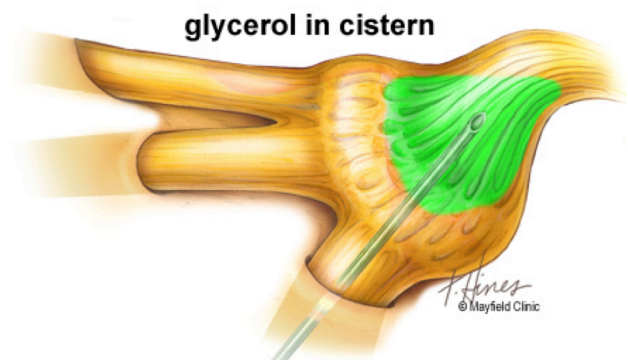


Figure 8B. In glycerol injection, alcohol (green) damages nerve fibers in the cistern; it is not selective to specific division of the nerve.

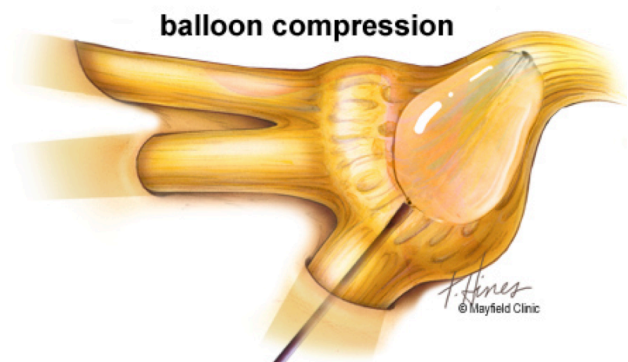


Figure 8C. In balloon compression, inflation compresses the nerve fibers; it may be selective.

## Clinical trials

Clinical trials are research studies in which new treatments—drugs, diagnostics, procedures, and other therapies—are tested in people to see if they are safe and effective. Research is always being conducted to improve the standard of medical care. Information about current clinical trials, including eligibility, protocol, and locations, are found on the Web. Studies can be sponsored by the National Institutes of Health (see [clinicaltrials.gov](http://clinicaltrials.gov)) as well as private industry and pharmaceutical companies (see [www.centerwatch.com](http://www.centerwatch.com)).

## Recovery

No one procedure is best for everyone and each procedure varies in its effectiveness versus side effects. Microvascular decompression (MVD) and radiofrequency rhizotomy (PSR) have comparable rates of long-term pain relief that are highest among the available options. In a study of approximately 100 patients published in the past 10 years, 77% of patients treated with MVD had pain relief for 7 years, while 75% treated with PSR rhizotomy had pain relief for 6 years. Of patients treated with radiosurgery, an appropriate treatment for those who cannot undergo MVD or who wish to avoid the facial numbness associated with PSR, 60% have pain relief for 5 years.

Trigeminal neuralgia can recur in divisions of the nerve previously free of pain. This can occur following all treatments and may represent progression of the underlying disorder rather than recurrence.

## Sources & links

If you have questions, please contact Springfield Neurological and Spine Institute at 417-885-3888.

## Support

Support groups provide an opportunity for patients and their families to share experiences, receive support, and learn about advances in treatments, pain control, and medications. Please contact the TNA Facial Pain Association at 800-923-3608.

## Sources

1. Taha JM, Tew JM Jr: Comparison of surgical treatments for trigeminal neuralgia: Reevaluation of radiofrequency rhizotomy. *Neurosurgery* 38:865-871, 1996.
2. Tew JM: Therapeutic Decisions in Facial Pain. *Clinical Neurosurgery* 46:410-431, 2000

3. Tuleasca C, Resseguier N, Donnet A, et al.: Patterns of pain-free response in 497 cases of classic trigeminal neuralgia treated with Gamma Knife surgery and followed up for at least 1 year. *J Neurosurg* 117 Suppl:181-188, 2012
4. Gronseth G, et al.: Practice Parameter: The diagnostic evaluation and treatment of trigeminal neuralgia (an evidence-based review). *Neurology* 71:1183-90, 2008

## Links

TNA Facial Pain Association [www.fpa-support.org](http://www.fpa-support.org)  
Trigeminal Neuralgia Diagnostic Questionnaire, <https://neurosurgery.ohsu.edu/tgn.php>

## Glossary

**anesthesia dolorosa:** constant pain felt in an area of total numbness; similar to phantom limb pain.

**anticonvulsant:** a drug that stops or prevents convulsions or seizures.

**dysesthesia:** a numbness, crawling, or unpleasant sensation that a person considers disturbing.

**glycerol:** an oily fluid that can be injected into a nerve to destroy its pain-producing portion.

**multiple sclerosis:** a chronic degenerative disease of the central nervous system in which the myelin surrounding the nerves is destroyed.

**neuralgia:** nerve pain.

**neurectomy:** cutting of a nerve to relieve pain.

**postherpetic neuralgia:** chronic pain that persists after shingles rash and blisters have healed.

**radiofrequency:** radiant energy of a certain frequency.

**rhizotomy:** interruption or destruction of a group of nerve fibers by chemical or radiowaves.

**shingles (herpes zoster):** a viral infection that causes a painful skin rash and blisters along the course of a nerve; a reactivation of chickenpox.



updated > 7.2018

reviewed by > Steven Bailey, MD and Ronald Warnick, MD, Mayfield Clinic, Cincinnati, Ohio

Mayfield Certified Health Info materials are written and developed by the Mayfield Brain & Spine. We comply with the HONcode standard for trustworthy health information. This information is not intended to replace the medical advice of your health care provider. © Mayfield Clinic 1998-2018.